

Cryopreserved Human Amniotic Membrane Injection for Plantar Fasciitis: A Randomized, Controlled, Double-Blind Pilot Study

Foot & Ankle International®
2015, Vol. 36(2) 151–158
© The Author(s) 2014
Reprints and permissions:
sagepub.com/journalsPermissions.nav
DOI: 10.1177/1071100714552824
fai.sagepub.com

Andrew E. Hanselman, MD¹, John E. Tidwell, MD¹,
and Robert D. Santrock, MD¹

Abstract

Background: Treatment options for plantar fasciitis have resulted in varied patient outcomes. The aim of this study was to compare a novel treatment, cryopreserved human amniotic membrane (c-hAM), to a traditional treatment, corticosteroid. Our hypothesis was that c-hAM would be safe and comparable to corticosteroids for plantar fasciitis in regard to patient outcomes.

Methods: A randomized, controlled, double-blind, single-center pilot study was completed. Patients were randomized into one of 2 treatment groups: c-hAM or corticosteroid. Patients received an injection at their initial baseline visit with an option for a second injection at their first 6-week follow-up. Total follow-up was obtained for 12 weeks after the most recent injection. The primary outcome measurement was the Foot Health Status Questionnaire (FHSQ). The secondary outcome measurements were the Visual Analog Scale (VAS) and verbally reported percentage improvement. Data were analyzed between groups for the 2 different cohorts (1 injection versus 2 injections). Twenty-three patients had complete follow-up. Fourteen were randomized to receive corticosteroid and 9 were randomized to receive c-hAM.

Results: Three patients in each group received second injections. With the numbers available, the majority of outcome measurements showed no statistical difference between groups. The corticosteroid did, however, have greater FHSQ shoe fit improvement ($P = .0244$) at 6 weeks, FHSQ general health improvement ($P = .0132$) at 6 weeks, and verbally reported improvement ($P = .041$) at 12 weeks in the one-injection cohort. Cryopreserved hAM had greater FHSQ foot pain improvement ($P = .0113$) at 18 weeks in the 2-injection cohort.

Conclusion: Cryopreserved hAM injection may be safe and comparable to corticosteroid injection for treatment of plantar fasciitis. This is a pilot study and requires further investigation.

Level of Evidence: Level I, prospective randomized trial.

Keywords: plantar fasciitis, amniotic membrane, placental membranes, cryopreservation, corticosteroid, heel pain

Plantar fasciitis is a painful foot disorder and the most common cause of heel pain in adults.²⁵ The disease has a bimodal age distribution, with a large peak between 40 and 60 years old and a smaller peak in athletes in their 20s.⁸ More prevalent in women, these patients often present with symptoms of start-up heel pain after periods of rest and worsening pain with overactivity.¹⁹ Clinically, these patients often demonstrate reproducible tenderness to palpation along the medial calcaneal tubercle.³⁰

Often mistaken as an inflammatory process, histological studies have identified plantar fasciitis as a degenerative process secondary to repetitive trauma.¹¹ Traditionally treated nonoperatively, first-line therapies involve resting of the affected limb, nonsteroidal anti-inflammatory drugs (NSAIDs), heel padding, orthotics, and stretching exercises.

These are often successful; however, more invasive second-line treatments are occasionally required. Currently, corticosteroids are the most utilized treatment modality, yet patient outcomes have been suboptimal and wide ranging. There are also risks involved with steroid use, including plantar fascia

¹Department of Orthopaedics, West Virginia University School of Medicine, Morgantown, WV, USA

Corresponding Author:

Andrew E. Hanselman, MD, Department of Orthopaedics, West Virginia University School of Medicine, Robert C. Byrd Health Sciences Center, West Virginia University, PO Box 9196, Morgantown, WV 26506-9196, USA.

Email: ahansell@hsc.wvu.edu

rupture.^{2,4,25} As a result, new treatment options are continually being investigated.

Fetal tissues, consisting of the amniotic membrane, chorionic membrane, and umbilical cord, are well known for their healing characteristics and are a potential therapeutic modality for plantar fasciitis. Secondary to numerous growth factors, cytokines, and matrix components, these tissues promote healing differently than normal adult tissues. They emphasize the regenerative stages, while limiting inflammation and scarring.^{1,13,22,24,27,31} As a result, fetal tissues have been used since the early 20th century as treatments for chronic wounds and burns.^{5,28} Since then, newer methods of preparation and storage have expanded its use into numerous operative fields.^{3,6,14,16,17,31-33}

With invasive treatment options for plantar fasciitis resulting in subpar outcomes, the aim of this pilot study was to investigate this novel treatment in comparison to the most established treatment method, corticosteroid injection. We specifically wanted to evaluate its short-term safety and effect on patient outcomes. After a thorough literature search, only 1 other study was found that evaluated the effects of placental membranes for plantar fasciitis, which showed promising results compared to a saline placebo.³⁵ Our hypothesis was that the use of cryopreserved human amniotic membrane (c-hAM) for plantar fasciitis would be safe and comparable in symptom improvement to traditional corticosteroids.

Methods

Design

We conducted a double-blind randomized controlled study comparing plantar fasciitis symptoms in patients that received either traditional corticosteroid (Depo Medrol, Pfizer, New York, NY) or c-hAM (AM3, now known as Clarix® FLO, Amnio Medical, Atlanta, GA). The study was conducted at a single center by a board certified orthopaedic surgeon, fellowship trained in foot and ankle surgery. Institutional review board (IRB) approval was obtained prior to initiation of the study.

Study Population

The study population consisted of male and female participants recruited for heel pain through institutional and community advertising. Advertisement funding was provided by a research grant from the study drug company. Inclusion criteria were patients 18 to 65 years old, clinical diagnosis of plantar fasciitis, symptoms present for a minimum of 3 months but less than 1 year, and without coexisting foot or ankle pathology. Exclusion criteria were ages younger than 18 years old or older than 65, previous plantar fasciitis injections, symptoms present for less than 3 months or

greater than 1 year, previous physician intervention within the past 3 months for plantar fasciitis, previous foot surgery or injury, lower extremity neuropathy, known allergy to corticosteroids, allergy to Ciprofloxacin or Amphotericin B, nonambulatory status, currently pregnant or breastfeeding, pregnant within the past 6 months, or unwilling to receive human tissue injection. No exclusions were based on race or gender.

Enrollment and Demographics

A sample size of 50 patients was chosen based on the average number of plantar fascia patients seen in our primary investigator's clinic over a 6-month period. Due to unexpected circumstances mentioned in the limitations section, we were able to enroll only 24 patients. One hundred thirteen patients responded to the advertising for heel pain and underwent initial telephone screening. Twenty-six patients were then evaluated in clinic by the primary investigator. Two patients did not have a diagnosis of plantar fasciitis and were considered ineligible for the study. Of the 24 patients consented and enrolled in the study, 96% (23/24) completed the required 12 weeks of follow-up and were included in the final data analysis. One subject was lost to follow-up. In all, 30% (7/23) were male and 70% (16/23) were female. The average age was 51 years old (range, 32-65). Fourteen patients were randomized to receive the corticosteroid injection (control group), 9 patients to receive the c-hAM injection (study group).

Evaluation and Randomization

Respondents to the advertising underwent an initial telephone screening based on inclusion and exclusion criteria. Patients with potential eligibility were then scheduled in clinic and evaluated by the primary investigator for plantar fasciitis through history and physical examination. Patients considered qualified for participation were consented using IRB-approved documentation and randomized into 1 of 2 groups: (1) control group—corticosteroid (1 mL of 40 mg/mL Depo Medrol, 4 mL bupivacaine 0.5%); (2) study group—c-hAM (1 mL AM3 [now Clarix FLO], 4 mL bupivacaine 0.5%).

Treatment

Preparation of both the control and study drugs was completed by our institution's investigational pharmacy department. The syringe barrel was covered and its contents blinded to both the investigators and the patients. All injections were performed by the primary investigator. Patients were placed in a supine position and the skin over the medial heel on the plantar aspect of the study foot was prepped with betadine. A sterile 25-gauge needle was

Table 1. Average FHSQ Score Change Compared to Baseline for I-Injection Cohort.

	Foot Pain	Foot Function	General Foot Health	Shoe Fit	General Health	Physical Activity	Social Capacity	Vigor
6 weeks (c-hAM)	21.6	17.7	12.5	-2.1	-13.3	21.3	8.3	4.2
6 weeks (steroid)	42.7	31.8	23.5	39.1	5.5	21.7	6.8	6.8
12 weeks (c-hAM)	19.3	25.0	13.9	14.6	6.7	15.7	6.3	18.8
12 weeks (steroid)	36.6	30.7	22.7	31.1	3.6	19.7	10.2	9.7

Higher score indicates improving symptoms.

inserted perpendicular to the skin surface and directed toward the medial calcaneal tuberosity down to the level of the periosteum. Approximately half of the syringe contents (~2.5 mL) was injected. The syringe was then withdrawn to immediately below the skin surface and redirected toward the midline of the foot. During this redirection, the tip of the needle was “dragged across” the fascia in an attempt to promote healing factors by causing minor insult to the fascia. At this point, the remaining contents of the syringe were injected (~2.5 mL). Upon completion of the procedure, patients were given written instructions, along with in-person demonstration, for plantar fascia and calf stretching exercises. They were instructed to perform these exercises a minimum of 5 times per day. Patients were not given any weight-bearing or activity restrictions; patients were also not given any braces or orthotics. This protocol was designed to represent the primary investigator’s standard treatment for plantar fasciitis.

Follow-Up

Following their baseline visit, patients were first reevaluated at 6 weeks. At that time, they were given the option of receiving a second injection at their own discretion. If they declined a second injection, they were reevaluated again in another 6 weeks resulting in 3 total clinic visits: initial visit (injection), 6-week follow-up, and 12-week follow-up. If patients chose to receive a second injection, they underwent the procedure as described above with the same drug that corresponded to their initial injection which was again blinded to both the investigator and the patient. The patient was reevaluated in another 6 and 12 weeks resulting in 4 total clinic visits: initial visit (injection), 6-week follow-up (second injection), 12-week follow-up, and 18-week follow-up. With both schedules, patients had 12 weeks of follow-up from their most recent injection. This protocol, with the option of a second injection, was again designed to represent the primary investigator’s standard treatment for plantar fasciitis.

Outcome Measurements

The primary outcome measurement at each visit, starting with the initial visit, was the Foot Health Status Questionnaire (FHSQ). The FHSQ is a validated measurement of foot

health and impact on quality of life that is divided into 4 foot-related subscales (foot pain, foot function, footwear, general foot health) and 4 overall health subscales (general health, physical activity, social capacity, vigor). Scores in each category are based on a scale from 0 to 100, with higher scores representing better foot health and quality of life.²⁶ Secondary outcome measurements included the Visual Analog Scale (VAS) and the patient’s verbally reported percentage improvement. The VAS is a measurement of pain intensity on a continuous scale from 0 to 100, with lower scores representing less pain symptoms.⁹ The patient’s verbal percentage improvement was documented at each visit with 0% representing no resolution of symptoms and 100% representing complete resolution of symptoms.

Data Collection

Patient enrollment occurred from August 2013 to January 2014. The data collection period ended in April 2014. FHSQ scores were calculated using the Foot Health Status Questionnaire Data Collection Program Version 1.03.

Statistical Methods

Comparisons between the control and study groups were performed separately for the 1-injection and 2-injection cohorts using Student’s *t* test. *P* values less than .05 were considered to be significant.

Results

Three patients in the control group and 3 patients in the study group received second injections. Results were analyzed between the 2 cohorts, 1 injection versus 2 injections.

Foot Health Status Questionnaire

An FHSQ score was obtained from each patient at baseline and at each follow-up visit (Tables 1 and 2). In the 1-injection group, shoe fit at 6 weeks ($P = .0244$) and general health at 6 weeks ($P = .0132$) were statistically greater in the control (steroid) group. In the 2-injection group, foot pain score at 18 weeks ($P = .0113$) was statistically greater in the study (c-hAM) group, indicating an improvement in

Table 2. Average FHSQ Score Change Compared to Baseline for 2-Injection Cohort.

	Foot Pain	Foot Function	General Foot Health	Shoe Fit	General Health	Physical Activity	Social Capacity	Vigor
6 weeks (c-hAM)	18.8	-2.1	-11.1	-20.0	-3.3	5.6	-20.8	-2.1
6 weeks (steroid)	24.6	8.3	33.3	20.0	-3.3	14.8	0.0	-8.3
12 weeks (c-hAM)	56.9	27.1	19.4	5.8	-3.3	33.3	0.0	10.4
12 weeks (steroid)	45.8	29.2	13.9	47.5	0.0	27.8	8.3	2.1
18 weeks (c-hAM)	66.3	31.3	33.3	27.5	3.3	33.3	-16.7	14.6
18 weeks (steroid)	32.5	33.3	5.6	52.5	-6.7	31.5	8.3	12.5

Higher score indicates improving symptoms.

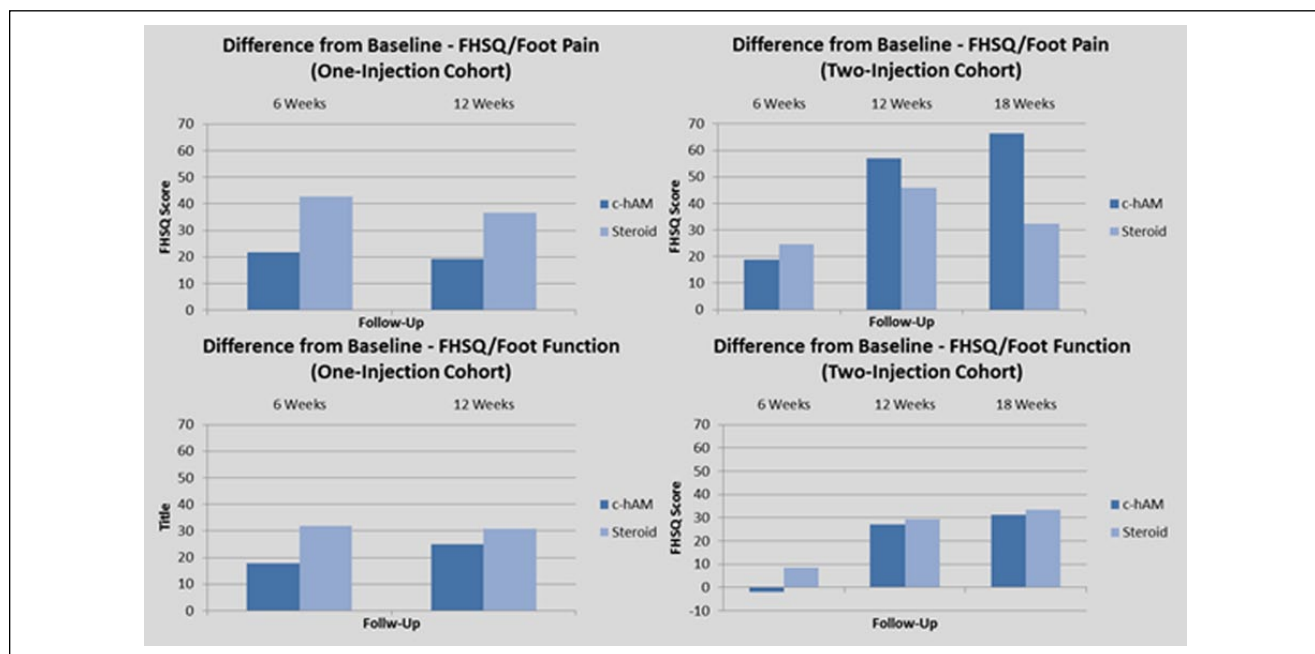


Figure 1. Foot Health Status Questionnaire score comparison (foot pain and foot function).

foot pain. All other variables resulted in no significant difference. There also appeared to be a dose-dependent effect among the c-hAM study group in regard to foot pain and foot function (Figure 1).

Visual Analog Scale Score

A VAS score was obtained from each patient at baseline and at each follow-up visit (Table 3). There was no significant difference between the control and study groups. There also appeared to be a dose-dependent effect in the c-hAM study group (Figure 2).

Patient-Reported Outcomes

Self-reported patient percentage improvement was documented at each follow-up visit (Table 4). Verbal percentage improvement at 12 weeks ($P = .041$) was statistically greater in the 1-injection steroid group. All other variables resulted

Table 3. Average VAS Score Change Compared to Baseline.

	VAS (1 Injection)	VAS (2 Injections)
6 weeks (c-hAM)	-13.0	-6.3
6 weeks (steroid)	-15.3	-14.5
12 weeks (c-hAM)	-17.8	-29.7
12 weeks (steroid)	-12.6	-28.0
18 weeks (c-hAM)	n/a	-37.3
18 weeks (steroid)	n/a	-25.7

Lower score indicates improving symptoms.

in no significant difference. There also appeared to be a dose-dependent effect among the c-hAM study group (Figure 3).

Complications

There were no adverse side effects experienced.

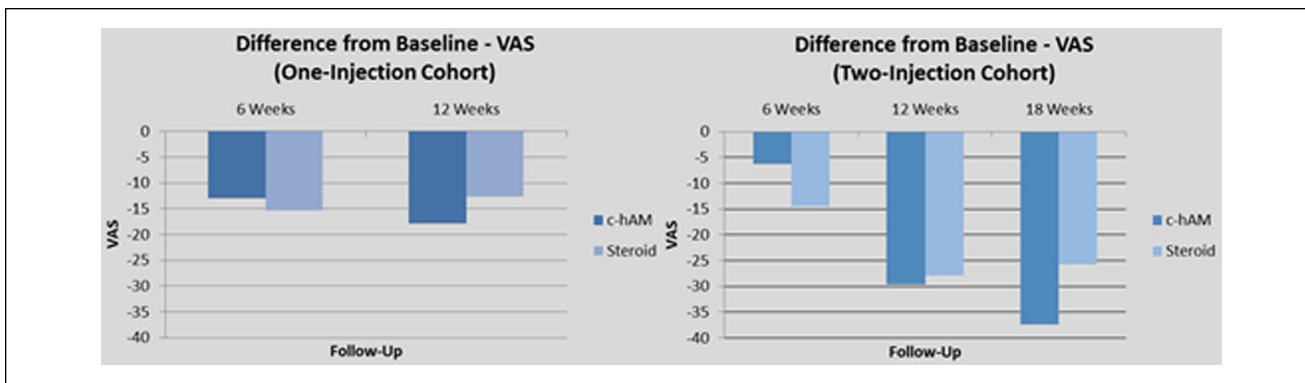


Figure 2. Visual Analog Scale score.

Table 4. Average Verbal Percentage Improvement Compared to Baseline for 2-Injection Cohort.

	% Improvement (1 Injection)	% Improvement (2 Injections)
6 weeks (c-hAM)	65.0	8.33
6 weeks (steroid)	81.8	68.3
12 weeks (c-hAM)	60.8	90.0
12 weeks (steroid)	87.7	89.7
18 weeks (c-hAM)	n/a	98.3
18 weeks (steroid)	n/a	75.0

Higher score indicates improving symptoms.

Discussion

To our knowledge, this is the first study in the orthopaedic literature to investigate fetal tissue use for plantar fasciitis in comparison with corticosteroids. This initial pilot study demonstrated that c-hAM may be a safe treatment option, as none of the patients reported any adverse events related to the product. It also showed that c-hAM treatment may be, at least, comparable to corticosteroid. In regard to the 1-injection cohort, the study group showed no significant difference compared to the 1-injection control group for our 3 most relevant outcomes: FHSQ (foot pain), FHSQ (general foot health), and VAS. We do acknowledge, however, that some of these variables showed greater improvement with corticosteroid use that would require more analysis with larger clinical trials. For the 2-injection cohort, there was a statistically significant improvement in the study group compared to the control group for FHSQ (foot pain). This cohort also demonstrated a dose-dependent response, along with the corticosteroid group, that would again need to be analyzed with future studies. Even though the numbers in our study may have been small, it is important for 2 main reasons. First, it shows that a human-derived tissue was safe and at least comparable to corticosteroids, which is not a benign treatment. Second, it establishes a foundation for future clinical trials, especially

on the dose-dependent effect of placental tissues after receiving a second injection.

A thorough review of the literature revealed only 1 previous study investigating placental membrane use for plantar fasciitis. Zelen et al conducted a prospective, randomized study evaluating different concentrations of micronized dehydrated human amniotic/chorionic membrane injection to a saline placebo.³⁵ Their study included 45 patients with 8 weeks of follow-up. Results showed statistically significant improvement in patient outcomes among the study group, specifically in regard to American Orthopaedic Foot and Ankle Society hindfoot scores. Although our control groups were different, Zelen et al’s investigation provided initial data showing a benefit to using placental membrane tissue for plantar fasciitis.

The amniotic membrane (AM), along with the chorionic membrane and umbilical cord, forms the fetal membranes. Transplantation of these tissues in previous studies have resembled the scarless fetal wound healing seen after intra-uterine procedures.^{1,31} They contain numerous growth factors and a natural scaffolding ability that promotes healing differently than normal adult tissue. These growth factors, epithelial growth factor, transforming growth factor alpha (TGFα), keratinocyte growth factor, hepatocyte growth factor, and basic fibroblast growth factor, shift the focus away from the initial inflammatory stage and late scarring stage, while emphasizing the middle reparative stage.¹³ This unique quality allows AM to suppress inflammation and limit the formation of scar tissue. Although studies have shown that plantar fasciitis is not an inflammatory process, it does have a major degenerative component that would benefit from the increased emphasis on reparative healing. Several different mechanisms for these actions have been proposed, including the down-regulation of the TGF-beta pathway and apoptosis of polymorphonuclear cells, macrophages, and other important components of the innate immune system.^{13,22,31} Other unique properties of fetal tissues are their epithelialization promotion, antimicrobial, and antipain characteristics.^{24,27,31}

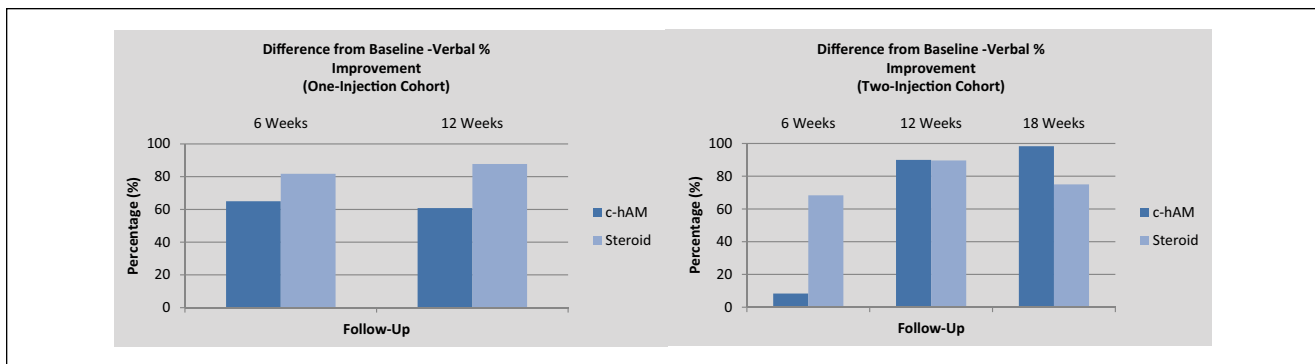


Figure 3. Verbal percentage improvement.

AM tissue has been utilized since the early 1900s, specifically for burns and chronic wounds.^{5,28} Since then, its utilization has expanded into several operative fields, including obstetrics and gynecology, general surgery, plastic surgery, neurosurgery, and urology.^{3,14,16,32,33} Perhaps the most well-known application, however, has been in the field of ophthalmology, where it has been used for almost 20 years, particularly with soft tissue corneal reconstruction.^{6,17,31} In 2001, it was approved by the Food and Drug Administration (FDA) for ocular surface reconstruction and was subsequently approved as a standard operative procedure by Medicare in 2004.³¹

Originally used in its natural form immediately after birth, newer methods of sterilization, preparation, and storage of the placental membranes have been developed to allow for broader clinical use.^{7,12} These tissues are obtained electively from donor mothers after healthy Cesarean sections, undergo testing regulated by the FDA and American Association of Tissue Banks, and are known for their low immunogenicity. Several different preparation and storage methods may be utilized; however, the particular formulation used in this study underwent cryopreservation through a CRYOTEK™ process (AmnioX Medical, Atlanta, GA). This process involves the freezing of the donor tissues while maintaining hydration to preserve the innate biological potential of the membrane. Other methods of preparation and storage are available through different manufacturers; however, most current methods are FDA-approved and provide for easy application in different operative settings.

With these improved methods of utilization over the past decade, fetal tissues are also starting to find their way into the orthopaedic community. Numerous preclinical and small clinical trials have evaluated their application for tendonitis, tendon repair, adhesion prevention, nerve repair, postoperative wounds, osteoarthritis, and spinal procedures.^{10,18,20,21,23,29} They are also being used for several foot and ankle applications, such as diabetic foot ulcerations and other types of chronic wounds.^{15,34,36}

Although this study was randomized, controlled, and double-blind, there are several limitations that need to be addressed. First, the sample size was lower than initially intended. We planned to enroll 50 patients based on the number of patients seen in our primary investigator's clinic over a 6-month period; however, a change in treatment drug formulation by the manufacturer occurred during the course of the study. This formula is no longer available through the manufacturer. Although the new formulation is reported to contain enhanced growth factors with improved healing potential, we decided that the validity of the study could not be maintained with use of 2 different formulations. As a result, this study will be used as the foundation for a larger clinical trial. Second, patients were recruited through community and institutional advertising, which creates the potential for a bias based on the fact that they were willingly involved in a clinical trial. The patients in this study were seeking treatment for their heel pain and, therefore, the compliance rate was high at 96% (23/24 patients), which may not be representative of the general population. Third, the follow-up for this study was 12 weeks from the most recent injection, which may be considered short term for other types of foot and ankle pathologies. However, this schedule is consistent with normal treatment standards for plantar fasciitis. This disease process tends to resolve with appropriate treatment within this time period. If patients' symptoms improve, longer follow-up may lead to loss of compliance. Finally, the increased cost of the study drug compared to the traditional corticosteroid injection should be noted. The list price for the study drug is \$1400. Although these costs vary based on several different factors, the study drug is comparable in price to platelet-rich plasma (PRP), while remaining less costly than other available treatments, such as shockwave therapy and operative intervention.

Conclusion

In summary, this study compared c-hAM to corticosteroid for treatment of plantar fasciitis and showed that it was safe to use and may be comparable to corticosteroids. To our

knowledge, this is the first study in the orthopaedic literature that compares this novel treatment to the traditional treatment. This pilot study, along with the study by Zelen et al, provides evidence that human-derived tissues, such as placental membranes, may be a safe and effective treatment method for a pathological process, such as plantar fasciitis. The data obtained in this pilot study will be used for development of future clinical trials.

Editor's Note

Both reviewers felt that the novelty of this treatment warranted publication. However, with the short follow-up period, it really shows only that it was safe in the short term and about equally effective to a corticosteroid injection. While corticosteroid injections have potential side effects, the high cost of this new agent needs to be kept in mind when deciding whether to utilize it. Clearly, longer term studies are needed to assess the results of this treatment.

Authors' Note

The views expressed in this submission are the authors' own and not a representation of the institution.

Declaration of Conflicting Interests

The author(s) declared no potential conflicts of interest with respect to the research, authorship, and/or publication of this article.

Funding

The author(s) declared the following financial support for the research, authorship, and/or publication of this article: Amnioc Medical Inc (Atlanta, GA).

References

- Adzick NS, Lorenz HP. Cells, matrix, growth factors, and the surgeon. The biology of scarless fetal wound repair. *Ann Surg*. 1994;220(1):10-18.
- Babcock MS, Foster L, Pasquina P, Jabbari B. Treatment of pain attributed to plantar fasciitis with botulinum toxin a: a short-term, randomized, placebo-controlled, double-blind study. *Am J Phys Med Rehabil*. 2005;84(9):649-654.
- Chou CT, Lee C, Hwang JL. Amniotic membrane used for vulvar adhesion treatment. *Arch Gynecol Obstet*. 2001;265(4):223-224.
- Cutts S, Obi N, Pasapula C, Chan W. Plantar fasciitis. *Ann R Coll Surg Engl*. 2012;94(8):539-542. doi:10.1308/003588412X13171221592456.
- Davis JW. Skin transplantation with a review of 550 cases at the Johns Hopkins Hospital. *Johns Hopkins Med J*. 1910;15.
- Dua HS, Gomes JA, King AJ, Maharajan VS. The amniotic membrane in ophthalmology. *Surv Ophthalmol*. 2004;49(1):51-77.
- Fetterolf DE. Scientific and clinical support for the use of dehydrated amniotic membrane in wound management. *Wounds*. 2012;24:299-307.
- Glazer JL. An approach to the diagnosis and treatment of plantar fasciitis. *Phys Sportsmed*. 2009;37(2):74-79. doi:10.3810/psm.2009.06.1712.
- Hawker GA, Mian S, Kendzerska T, French M. Measures of adult pain: Visual Analog Scale for Pain (VAS Pain), Numeric Rating Scale for Pain (NRS Pain), McGill Pain Questionnaire (MPQ), Short-Form McGill Pain Questionnaire (SF-MPQ), Chronic Pain Grade Scale (CPGS), Short Form-36 Bodily Pain Scale (SF-36 BPS), and Measure of Intermittent and Constant Osteoarthritis Pain (ICOAP). *Arthritis Care Res*. 2011;63:240-252. doi:10.1002/acr.20543.
- He Q, Li Q, Chen B, Wang Z. Repair of flexor tendon defects of rabbit with tissue engineering method. *Chin J Traumatol*. 2002;5(4):200-208.
- Jarde O, Diebold P, Havet E, Boulu G, Vernois J. Degenerative lesions of the plantar fascia: surgical treatment by fasciectomy and excision of the heel spur. A report on 38 cases. *Acta Orthop Belg*. 2003;69(3):267-274.
- John T. Human amniotic membrane transplantation: past, present, and future. *Ophthalmol Clin North Am*. 2003;16(1):43-65.
- Koizumi NJ, Inatomi TJ, Sotozono CJ, et al. Growth factor mRNA and protein in preserved human amniotic membrane. *Curr Eye Res*. 2000;20(3):173-177.
- Koziak A, Salagierski M, Marcheluk A, Szczesniewski R, Sosnowski M. Early experience in reconstruction of long ureteral strictures with allogenic amniotic membrane. *Int J Urol*. 2007;14(7):607-610.
- Letendre S, LaPorta G, O'Donnell E, Dempsey J, Leonard K. Pilot trial of biovance collagen-based wound covering for diabetic ulcers. *Adv Skin Wound Care*. 2001;22(4):161-166. doi:10.1097/01.ASW.0000305463.32800.32.
- Lin YH, Hwang JL, Huang LW, Chou CT. Amniotic membrane grafting to treat refractory labial adhesions postpartum. A case report. *J Reprod Med*. 2002;47(3):235-237.
- Liu J, Sheha H, Fu Y, Liang L, Tseng SC. Update on amniotic membrane transplantation. *Expert Rev Ophthalmol*. 2010;5(5):645-661.
- Meng H, Li M, You F, Du J, Luo Z. Assessment of processed human amniotic membrane as a protective barrier in rat model of sciatic nerve injury. *Neurosci Lett*. 2011;496(1):48-53. doi:10.1016/j.neulet.2011.03.090.
- Neufeld SK, Cerrato R. Plantar fasciitis: evaluation and treatment. *J Am Acad Orthop Surg*. 2008;16(6):338-46.
- Ozbuluk S, Ozkan Y, Ozturk A, et al. The effects of human amniotic membrane and periosteal autograft on tendon healing: experimental study in rabbits. *J Hand Surg Eur*. 2010;35(4):262-268. doi:10.1177/1753193409337961.
- Ozgenel GY, Filiz G. Effects of human amniotic fluid on peripheral nerve scarring and regeneration in rats. *J Neurosurg*. 2003;98(2):371-377.
- Park CY, Kohanim S, Zhu L, Gehlbach PL, Chuck RS. Immunosuppressive property of dried human amniotic membrane. *Ophthalmic Res*. 2009;41(2):112-113. doi:10.1159/000187629.
- Philip J, Hackl F, Canseco JA, et al. Amnion-derived multipotent progenitor cells improve Achilles tendon repair in rats. *Eplasty*. 2013;13:e31.
- Riau AK, Beuerman RW, Lim LS, Mehta JS. Preservation, sterilization and de-epithelialization of human amniotic

- membrane for use in ocular surface reconstruction. *Biomaterials*. 2010;31(2):216-225. doi:10.1016/j.biomaterials.2009.09.034.
25. Riddle DL, Schappert SM. Volume of ambulatory care visits and patterns of care for patients diagnosed with plantar fasciitis: a national study of medical doctors. *Foot Ankle Int*. 2004;25(5):303-310.
 26. Riskowski JL, Hagedorn TJ, Hannan MT. Measures of foot function, foot health, and foot pain: American Academy of Orthopedic Surgeons Lower Limb Outcomes Assessment: Foot and Ankle Module (AAOS-FAM), Bristol Foot Score (BFS), Revised Foot Function Index (FFI-R), Foot Health Status Questionnaire (FHSQ), Manchester Foot Pain and Disability Index (MFPDI), Podiatric Health Questionnaire (PHQ), and Rowan Foot Pain Assessment (ROFPAQ). *Arthritis Care Res (Hoboken)*. 2011;63:11. doi:10.1002/acr.20554.
 27. Robson MC, Krizek TJ. The effect of human amniotic membranes on the bacteria population of infected rat burns. *Ann Surg*. 1973;177(2):144-149.
 28. Sabella N. Use of fetal membranes in skin grafting. *Med Records NY*. 1913;83:478-480.
 29. Tao H, Fan H. Implantation of amniotic membrane to reduce postlaminectomy epidural adhesions. *Eur Spine J*. 2012;18(8):1202-1212. doi:10.1007/s00586-009-1013-x.
 30. Toomey EP. Plantar heel pain. *Foot Ankle Clin*. 2009;14(2):229-245. doi:10.1016/j.fcl.2009.02.001.
 31. Tseng SC, Li DQ, Ma X. Suppression of transforming growth factor-beta isoforms, TGF-beta receptor type II, and myofibroblast differentiation in cultured human corneal and limbal fibroblasts by amniotic membrane matrix. *J Cell Physiol*. 1999;179(3):325-335.
 32. Yan ZJ, Zhang P, Hu YQ, et al. Neural stem-like cells derived from human amnion tissue are effective in treating traumatic brain injury in rat. *Neurochem Res*. 2013;38(5):1022-1033. doi:10.1007/s11064-013-1012-5.
 33. Yetkin G, Uludag M, Citgez B, et al. Prevention of peritoneal adhesions by intraperitoneal administration of vitamin E and human amniotic membrane. *Int J Surg*. 2009;7(6):561-565. doi:10.1016/j.ijsu.2009.09.007.
 34. Zelen CM. An evaluation of dehydrated human amniotic membrane allografts in patients with DFUs. *J Wound Care*. 2013;22(7):347-351.
 35. Zelen CM, Poka A, Andrews J. Prospective, randomized, blinded, comparative study of injectable micronized dehydrated amniotic/chorionic membrane allograft for plantar fasciitis—a feasibility study. *Foot Ankle Int*. 2013;34(10):1332-1339. doi:10.1177/1071100713502179.
 36. Zelen S, Denoziere F. A prospective randomised comparative parallel study of amniotic membrane wound graft in the management of diabetic foot ulcers. *Int Wound J*. 2013;10:502-507. doi:10.1111/iwj.12097.